



PATIENT PRESENTING CLINICAL SIGNS

Koko Graham History: Lethargy, anorexia, and yellow diarrhea with previous history of 4-6 weeks duration of mild to moderate anemia with partial regeneration.

SPECIES

Physical Examination: Mild peripheral edema, icterus weight loss.

Canine

Urinalysis: Bilirubinuria.

BREED

CBC: Severe regenerative anemia, thrombocytopenia, neutrophilia, monocytosis.

Flat coat Retriever

Serum Biochemistry: Hypoproteinemia, elevated bilirubin.

Radiographic Findings: N/A.

SEX

FS

AGE

7 years

WEIGHT

20.5 kg

ULTRASONOGRAPHIC EXAMINATION OF THE ABDOMEN

Urinary System

Full urinary bladder with a normal thickness and appearance of the wall. Small amount of floating hyperechogenic sediment. No uroliths evident.

Normal trigone area, proximal urethra, and iliac blood vessels.

Normal iliac lymph nodes. Ureters not visualized.

Normal renal size (left 6.8 cm, right 7.2 cm), echogenic appearance, cortico-medullary differentiation, blood flow, pelvis, and capsule.

Adrenal Glands

Normal shape, echogenic appearance, and position. Normal size of the left adrenal (0.53 cm). Plump appearance of the right cranial pole (0.99 cm) with a normal length (2.59 cm) and width of caudal pole (0.59 cm).

Spleen

Enlarged (2.3 cm) and irregular with a diffuse mottled echogenic appearance. Large mottled echogenic mass (7.3 cm) in the tail of the spleen with bulging of the capsule.

Liver

Normal size with a diffuse hyperechogenic appearance, and some loss of portal markings. No nodules or masses evident. Small gall bladder containing normal anechoic bile. Normal appearance and thickness of the gall bladder wall. Normal bile duct.

Gastrointestinal

Normal appearance of the stomach, duodenum, small intestine, ileo-cecal junction, and colon with no loss of layering, normal wall thickness, and no loss of layering or distension of the lumen. Normal appearance of the gastric wall. Small amount fluid in the stomach and cranial small intestine.

INTERPRETED BY

Remo Lobetti, BVSc,
MMedVet (Med), PhD,
Dipl. ECVIM

IMAGING PERFORMED BY

Dr Alastair Westcott

HOSPITAL NAME

Mountainside Animal
Hospital

REFERRING VET

Dr Alastair Westcott

INVOICE

302536

DATE

8/31/21



PATIENT *Pancreas*

Koko Graham Normal size (Left 2.4 cm, right 1.3 cm) with a diffuse hyperechogenic appearance. Irregular capsule. Normal echogenic appearance of the mesentery and fat surrounding the pancreas.

SPECIES *Free Abdomen*

Canine Mesenteric lymphadenomegaly.
Small amount of ascites

BREED

Flat coat Retriever

ULTRASONOGRAPHIC FINDINGS

Primary Findings:

- Splenic pathology.
- Splenic mass.
- Hepatopathy.
- Lymphadenomegaly.
- Right adrenal nodule.
- Ascites.

SEX

FS

AGE

7 years

WEIGHT

20.5 kg

Secondary Findings:

- Urinary bladder sediment.
- Pancreatic fibrosis.

INTERPRETED BY

Remo Lobetti, BVSc,
MMedVet (Med), PhD,
Dipl. ECVIM

INTERPRETATION OF THE FINDINGS & FURTHER RECOMMENDATIONS

Etiologies for the spleen would be reactive hyperplasia, extra-medullary hematopoiesis, splenitis, hypersplenism, and neoplasia. The most likely etiology for the splenic mass would be neoplasia (hemangioma, hemangiosarcoma, solid sarcoma) with granulomatous disease a differential diagnosis.

Etiologies for the hepatopathy would be secondary to the anemia, vacuolar, reactive, metabolic, acute/chronic hepatitis, and infiltrative neoplasia.

Etiologies for the lymphadenomegaly would be reactive, lymphadenitis, and infiltrative neoplasia.

Although the right adrenal nodule is most likely an incidental finding, emerging neoplasia should be considered.

The most likely etiology for the ascites would be secondary to the splenic and hepatic pathology and lymphadenomegaly as well as the hypoproteinemia.

Although the urinary bladder sediment is most likely an incidental finding, bacterial cystitis needs to be considered.

The appearance of the pancreas is typical for pancreatic fibrosis.

With the splenic and hepatic changes and the lymphadenomegaly, secondary IMHA would be the primary diagnosis.

IMAGING PERFORMED BY

Dr Alastair Westcott

HOSPITAL NAME

Mountainside Animal
Hospital

REFERRING VET

Dr Alastair Westcott

INVOICE

302536

DATE

8/31/21



PATIENT

Koko Graham

Further assessment would be urine culture, screening for vector-borne disease (4Dx, PCR), 3-view thoracic radiographs, and FNA cytology of the spleen, splenic mass, liver, and mesenteric lymph nodes. Once stabilized splenectomy and biopsies of the mesenteric lymph nodes should be considered.

SPECIES

Canine

Specific therapy would be dependent on an etiological diagnosis.

BREED

Flat coat Retriever

IMAGES

Liver

SEX

FS

AGE

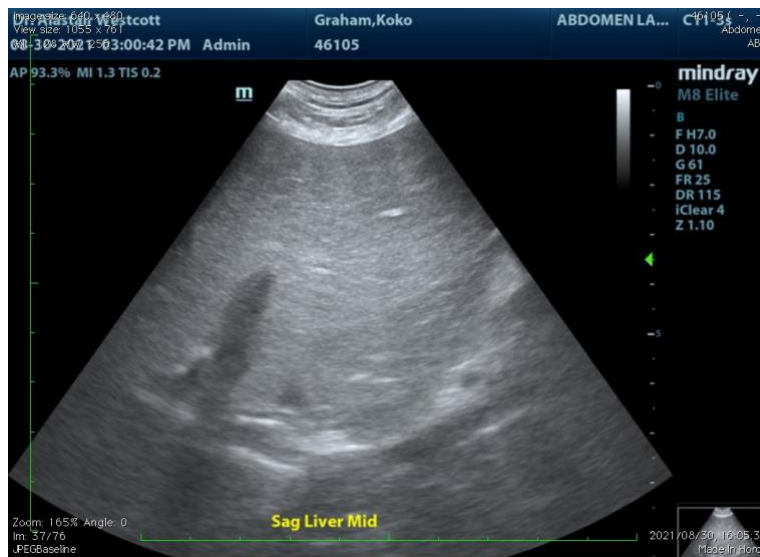7 years

WEIGHT

20.5 kg

INTERPRETED BY

Remo Lobetti, BVSc,
MMedVet (Med), PhD,
Dipl. ECVIM



Splenic mass

IMAGING PERFORMED BY

Dr Alastair Westcott

HOSPITAL NAME

Mountainside Animal
Hospital

REFERRING VET

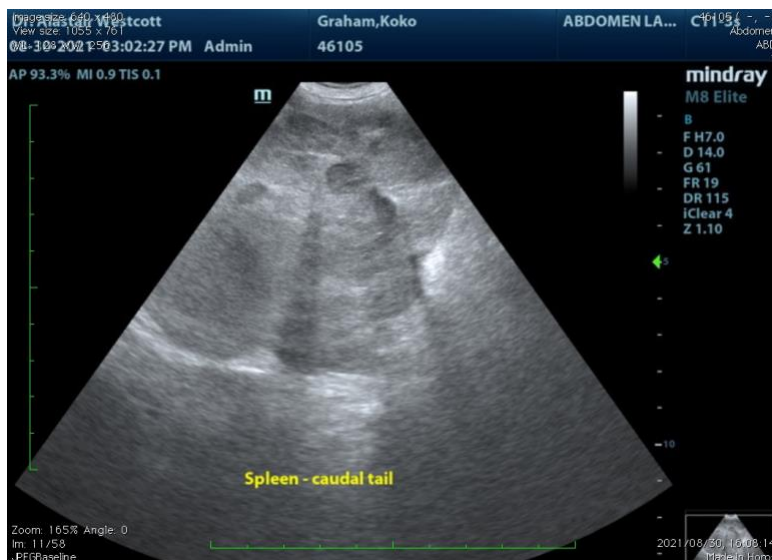Dr Alastair Westcott

INVOICE

302536

DATE

8/31/21





PATIENT Spleen

Koko Graham

SPECIES

Canine

BREED

Flat coat Retriever

SEX

FS

AGE

7 years

WEIGHT

20.5 kg

INTERPRETED BY

Remo Lobetti, BVSc,
MMedVet (Med), PhD,
Dipl. ECVIM

IMAGING PERFORMED BY

Dr Alastair Westcott

HOSPITAL NAME

Mountainside Animal
Hospital

REFERRING VET

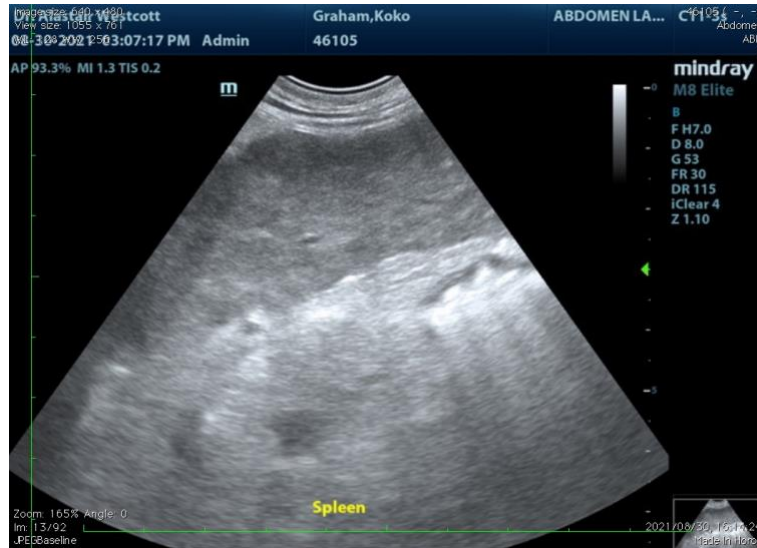Dr Alastair Westcott

INVOICE

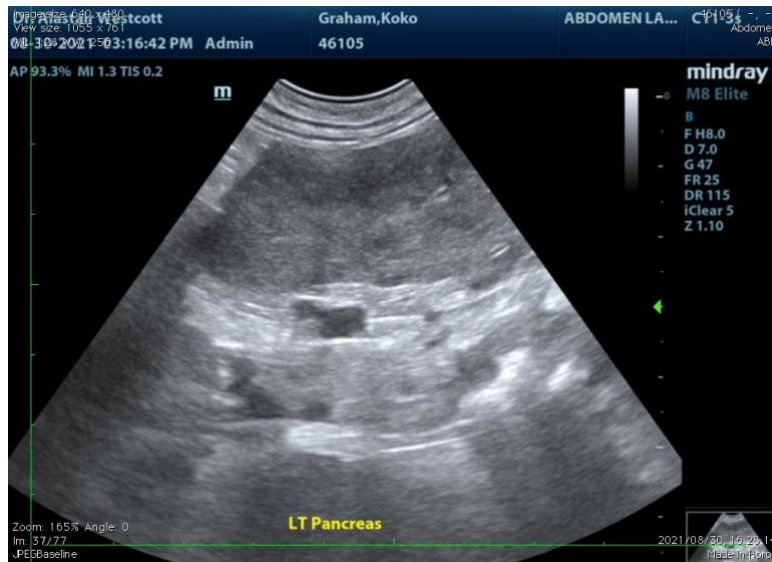302536

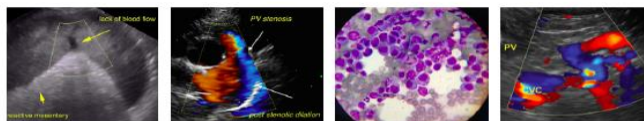
DATE

8/31/21



Pancreas/spleen





PATIENT Right adrenal

Koko Graham

SPECIES

Canine

BREED

Flat coat Retriever

SEX

FS

AGE

7 years

WEIGHT

20.5 kg

INTERPRETED BY

Remo Lobetti, BVSc,
MMedVet (Med), PhD,
Dipl. ECVIM

IMAGING PERFORMED BY

Dr Alastair Westcott

HOSPITAL NAME

Mountainside Animal
Hospital

REFERRING VET

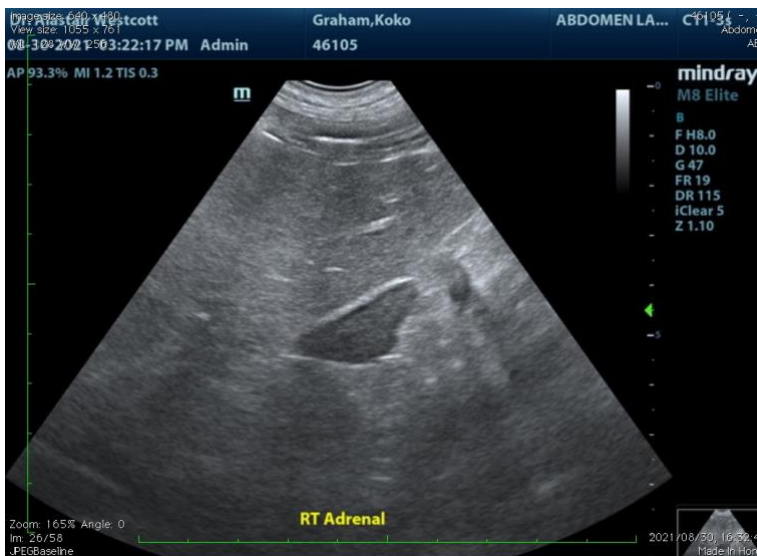Dr Alastair Westcott

INVOICE

302536

DATE

8/31/21



The information and recommendations provided are based on the images presented by the referring veterinarian. No evaluation can be communicated regarding pathology that was not visible in the image/video clips provided.

Thank you for this referral. If the clinical or image interpretation does not parallel your findings or if I can be of any further assistance, please contact me.

Remo Lobetti, BVSc, MMedVet (Med), PhD, Dipl. ECVIM (Internal Medicine)
rlobetti@mweb.co.za